

Access this article online

Quick Response Code:



Website:

www.carcinogenesis.com

DOI:

10.4103/jcar.jcar_23_01_09

Histological Influences and the Weight Measurements Study of Livers of a Spasmine Drug on the Embryos and White Pregnant Rat

Shaymaa Malik Yasir¹, Hanaa Mumtaz Hussein², Dalal Abdel-Hussein Kadhim AL-Essawi²

Abstract

Study was conducted to determine the role of spasming drug in certain weight and histological parameters of the livers I the embryos and pregnant rats on the 19th day of gestation. The study was carried out in the Education Faculty of Girls at Kufa University during the period of time from January 1, 2022 to June 15, 2022. After obtaining an adequate number of pregnant rats, some were given a dose of a physiological solution, this group represented the control (G1). At the same time, the other animal group of pregnant female rats were given in spasming drug at the dose of (0.48 mg/kg / b.w.) (G2), the pregnant rats in the control group had age (12) weeks and weight (233) grammes, and the pregnant animals in the spasming group had age (11) weeks and weight (229) grammes. Results of the study recorded a significant decrease (P 0.05) in the liver weights of each pregnant animals and embryos in the rat groups treated with the spasming drug during the 19th day of gestation. This was compared with the pregnant rat and embryo liver weights in the regulated groups during gestation for 19th day. Additionally, the results demonstrated that treating pregnant animals with spasming drugs till the 19th day of gestation stimulated various abnormal effects. The conclusion of this study: The treatment of pregnant rats with spasming drugs reduced the weights of their livers. It caused various histopathological changes in the structure of the livers of the embryos and pregnant rats during gestation of the 19th day. Histopathological changes in the structure of the livers of the embryos and pregnant rats during the 19th day of gestation.

Keywords:

Spasmine, Weights, Livers, Embryo, Pregnant, Rats, Rattus.

Introduction

Medical drugs are prescribed for the treatment of many diseases, as each drug has a therapeutic effect for different diseases but these drugs may cause many side effects that may be mild in some or severe in other types of them which affect different body systems and since the wrong and unauthorized use of drugs induces dangerous and threatening effects on humans^[1]. Some studies have pointed to that different drugs may pass through the placenta from the mother to the embryo during the different stages of gestation causing harmful effects in the body systems

of pregnant women and their embryos alike because these drugs when they enter the body the pharmacological action is not limited to the affected organs but they cause harmful effects on the healthy organs of the body as well when they are present in them because they stimulate disorders in their metabolic functions^[2,3]. As these drugs have the ability to stimulate congenital disorders in embryos during gestation and newborns after birth and even adults alike which may cause death and for this reason many drugs are prepared during the different stages of gestation to ensure the safety of these medical drugs because the stage of gestation is critical for mothers as well as embryos^[4]. The spas mine medication is classified as a p-methoxy benzoic acid^[5].

This is an open-access journal, and articles are distributed under the terms of the Creative Commons Attribution-Non-Commercial-Share Alike 4.0 License, which allows others to remix, tweak, and build upon the work non-commercially, as long as appropriate credit is given and the new creations are licensed under the identical terms.

For reprints contact: editor@carcinogenesis.com

How to cite this article: Shaymaa Malik Yasir et al. Histological Influences and the Weight Measurements Study of Livers of a Spasmine Drug on the Embryos and White Pregnant Rats. J Carcinog 2024; 23(1):61-69

¹ Biology Department-College of Education for pure sciences- Kerbala University- Kerbala -Iraq.
² Biology Department- Education for Girls Faculty- Kufa University- Iraq.

Address for correspondence:

Shaymaa Malik Yasir,
Biology Department-College of Education for pure sciences- Kerbala University- Kerbala -Iraq.
E-mail: shaimaa.malik@uokerbala.edu.iq

Submitted: 18-April-2023
Revised: 20-Oct-2023
Accepted: 22-Dec-2023
Published: 05-Jan-2024

derivative and is commonly used to treat gastrointestinal disorders. Specifically, it functions as an antispasmodic to alleviate symptoms associated with chronic irritable colon, colitis of spastic and mucous and irritable bowel syndrome, and spastic constipation. Its mechanism of action involves direct sedation and muscle relaxation of the smooth muscles within the digestive system, thereby reducing painful cramps^[6, 7].

Additionally, Spasmin is effective in treating accompanying symptoms of irritable bowel syndrome, including intestinal colic, flatulence, diarrhea, constipation, and the passage of small, hard stools^[8]. The exact mechanism of action of this drug is still unknown but it is considered one of the antispasmodic effect through its direct activity on a smooth muscles of the digestive system and this causes these muscles to relax without impacting the normal bowel movement and several mechanisms were postulated to construe the action of spasmin on the digestive system, and the most important one is that the inhibition of receptors for acetylcholine, alters in the process for water absorption, reduced permeability of ion channels, local anesthetic effects in addition to the reuptake inhibitor of norepinephrine^[9, 10].

Spasmin drugs comes in multiple forms such as oral capsules and pills in addition to oral liquid ^[11], the efficiency of this drug begins about an hour after taking it and the patient feels the disappearance of pathological symptoms after (1-3) hours of implementing the drug but this period may increase depending on the health status of patients^[12], spasmin drug is like any other drug whose use is supported by some side effects like as loss of appetite, dry mouth, skin irritation headache, insomnia, depression, heartburn, indigestion, difficulty sleeping, diarrhea, feeling unwell and tired, slow heartbeat, immune system disorders such as allergic responses causing hypersensitivity which appear in the form of skin rashes, urticaria and facial edema, taking this drug with other drugs or certain meals may cause interactions that may reduce the effectiveness of the drugs used as the effectiveness of one drug might reduce the effectiveness of the other drug or may affect the patient's health^[13, 14].

Purpose of The Study

Due to the lack of research and studies on the impact of spasmin on the tissue of the liver during pregnancy, the purpose of present study that investigation potential impact of spasmin drugs of weights as well as histological structures of the livers of embryos and pregnant animals of rats for gestation of nineteenth day.

Materials and Methods

Study Animals

White female of rat animals from species *Rattus* with ages (12 weeks) and weights (233g) were used, along

with white male of rats from same species in a typical age (11 weeks) and a weights (229 g). These animals were obtained to the College of Sciences / University of Kufa, and both sexes were housed in plastic cages with identical ventilation, temperature, and lighting conditions^[15].

The Drug Dose

Spasmin drug used in the study was in the form of pills with a dose of (100) mg, then the concentration used in this study was prepared depending on the weight of the animals and then dosed to pregnant rats^[16, 17].

Preparing Pregnant Rats

To obtain pregnant female rodents, a single adult female rat was placed with one fertile male rat in every pairing up a cage in the evening, and the animals were left overnight^[18].

The following morning, the female rats were tested for seeing the vaginal plug in the female's vagina or in cage and as depicted in(figure -1) and it was determined that gestation had occurred based on the presence of the vaginal plug, which was thought about the zero-day of gestation^[19].

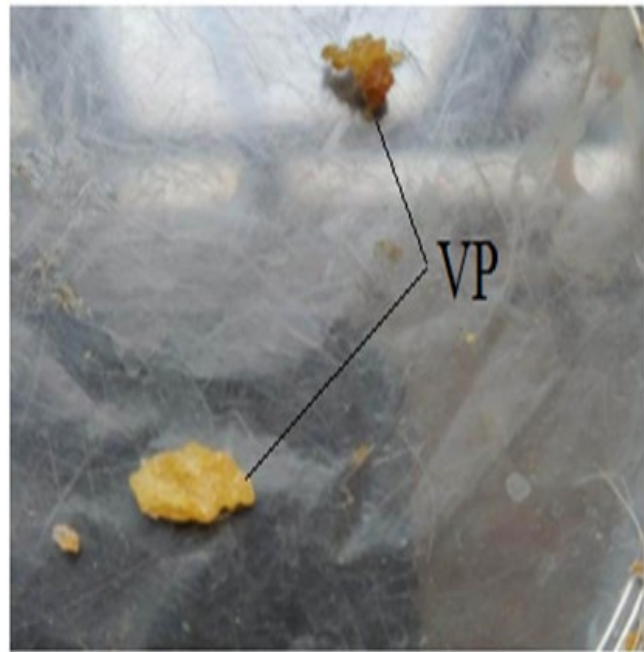


Image 1: Vaginal Plugs

Treatment of Pregnant Rats

This study's main experiment was designed to examine the probable side impacts of spasmin on weights and tissue modifications of livers in embryos and pregnant rat animals treated of this drug during gestation for 19th day.

After mating male and female rats and obtaining pregnant rats, all pregnant rats received treatment by peritoneal intramembranous injection at the rate of one injection per day for 19 days of gestation.

Pregnant Rats Dissection

Pregnant rats were annotated on the 20th day of gestation after being anesthetized with chloroform the pregnant rodents were pinned to a dissection dish before the abdominal cavity was cut open with pointed scissors., the livers of the pregnant rats were extracted and washed with a physiological solution and dried with filter paper, and their weight was measured by a normal weight balance, the uterine horns containing the embryos were also removed after removing the connective tissue and the fatty substances attached to it.

Embryos Dissection

After pregnant female rats dissection during gestation for 20th days, the two uterus horns and its contents of the embryos, then two horns of the uterus were opening by scissors to extract the embryos which were washed with physiological solution and dried with filter paper, then the embryos were anesthetized by placing a quantity of chloroform in the cotton, after that they were dissected by opening the cavity abdominal and the livers were extracted from the body and their weights were measured with a sensitive balance, then embryo livers were preserved with formalin solution at a concentration of 10% for 48 hours in order to prepare them for histological sections.

Histological Sections Pregnant Rats Livers and Embryos

During gestation for 19th days, tissue sections of livers of pregnant animals and embryos of them were made using method^[20].

Examination of Histological Liver Sections

The sections of liver tissues of all pregnant rats and their embryos during gestation for 19th days were prepared, then these tissue sections were examined and photographed using a MEIJT light micro tope equipped with a Samsung imaging camera installed on the microscope and on the powers (10X and 40X) respectively.

Statistically Data Analysis

Study data were done by using the statistical system (SPSS) for version 21, values were mean \pm standard error and ($P < 0.05$) was a probability level used in this study to extract least significant difference (LSD) for determining the significant differences among the groups.

Results & Discussion

Results of that studying revealed a significant decrease at the probability level ($P < 0.05$) in the liver weights of pregnant rats and embryos in the spasmine drug-treated pregnant rat group during the 19th day of gestation respectively when compared with the pregnant rat animals liver weights and embryos in group of control in a day 19 of gestation as shown in tables (1,2) respectively, as for the results of the histological study of the the livers of the embryos whose mothers were

handled with the spasmine drug suffered from different pathological effects on its histological structure and it was represented by the loss of the general structure of the hepatic tissue which may be a result of the lack of development and growth of a hepatic tissue while in the developed tissue can be observed many pathological changes such as destruction of the central vein wall, necrosis and degeneration of hepatocyte, expanding of sinusoids, congestion and necrosis of hepatic tissue , bleed clotting and inflammatory cell infiltration as shown in the figures (2,3,4, 6,7,8,9,10,11,12,13,14) respectively.

when compared with the normal histological framework of the livers of embryos in the control group ,figures (1,5) and the examination results of histological sections of pregnant rats livers in control animals throughout 19th day of gestation which did not show any abnormal changes in the as shown in the figures (15,19) respectively while the histological results of sections of pregnant female livers that were given with spasmin during the 19th day of gestation demonstrated different histopathological changes represented by expansion and destruction of the central vein wall, necrosis and degeneration of hepatocyte, widening of sinusoids, bleeding into hepatic tissue and blockages , necrosis and damage of hepatic tissue and inflammatory cell infiltration as in the figures (16,17,18, 20,21,22,23,24,25,26) respectively.

In view of lack of sufficient researches of spasmine drug effect on weights and structure of the various organ tissues of the body especially the liver in pregnant rats during gestation or not or in embryos throughout the different stages of gestation therefore, these results in this research can be attributed to the fact that spasmine drug caused the decrease in pregnant animal liver weights and the embryos due to its toxic effect which stimulated pathological effects on the histological structure of the liver during gestation as a result of its induction of programmed cell passing away (Apoptosis) and necrosis in addition to the occurrence of degenerative changes in it causing a destruction of the hepatic tissue and others organ tissues of the rats and the failure of the development and destruction of the liver tissue of their embryos causing decrease in the weight of the livers in them and this is what the electricity study showed^[21, 22].

It may be because that spasmine drug is the cause of the destruction of various pregnant rats' tissues, especially the horns of the uterus and placenta leading to a decrease the getting of oxygen and various nutrients necessary for growth to embryos during gestation which triggered the destruction of different body tissues like livers and its absence of their growth and low weights^[23].

As for the histopathological effects induced by the drug under study in the liver tissues of pregnant rats and embryos during nineteen days of gestation it may be due to the ability of spasmine drug on the generation of free

radicals in cells and organs of the body in general and liver tissue cells particularly causing programmed death of cells and necrosis thus destroying and wrecking liver tissue [24].

As the production of free radicals, which are potent oxidizing factors, stimulates the oxidation process of lipids in cell membranes as well as other essential macromolecules inside cells such as nuclear acidic substances (DNA), proteins, and others, causing oxidative stress to every part of the body including cells of the liver tissue, which ultimately results in necrosis of the cells for the various tissues and thus destroys them, this may be attributed to the fact that free radicals are effective oxidising factors ,the free oxygen radicals arising from various medical drugs including spasmine plays a consequential role in the breakdown in body organs[25, 26].

As they are strong oxidizing agents for lipids in cell membranes causing their destruction especially when there levels exceed normal levels stimulating oxidative stress which leads to the depletion for various self-antioxidants in the body that it works to inhibit a activity of free radicals and stop their destructive action to the cells of various organs but when the levels for free radicals exceed the levels of antioxidants and the destructive action of cells as well as tissues of these free radicals will increase stimulating distinct histological impacts on the tissue structure of the liver and other body systems in pregnant rats and eggs in which the systems of the defense against antioxidants is weak and that they are not developed to counter the action of free radicals generated by the drug when it passes from the mother to an embryo through the placenta blood leading to oxidative destruction in the fetal tissues and stimulating histopathological effects in them[27-29].

Since these free radicals cause the devastation of mother's tissues such as the uterus and placenta and what they contain of blood vessels which leads for a failure to reach the blood that provides oxygen as well as other nutrients to the cells as a result of necrosis and degeneration of the cells of these blood vessels and as an result the tissue cells are exposed to a lack of oxygen and nutrition necessary for cells to carry out their various functions and these promote harmful histological effects on body organs[30].

Results of embryos livers

Table 1- Spasmine Medication Effects on Embryos Liver Weights During the 19th Day of Gestation.

Treatments	Liver weights Of Embryos (g)
	M± SE
Control Group(G1)	0.150 ± 0.002
Spasmin Drug Treated Group(G2)	0.071 ± 0.005 &
Least Significant Difference(LSD)	0.350

&: The Significant differences of administered group with control group at (P<0.05).

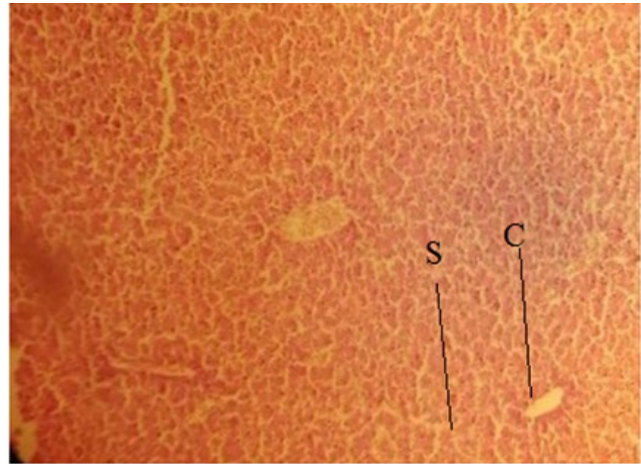


Figure 1: Is a cross slice of the following organs in the rat fetus liver of a control group during the 19th day of gestation: Hepatic tissue should have the following normal structure: Central vein (C), sinusoids (S) (H & E -stain, 10x).

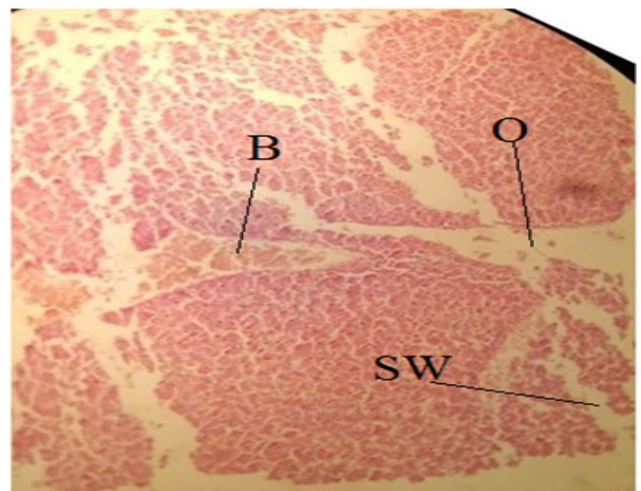


Figure 2: is a cross slice of rat fetus liver that was administered with the spasmine medication for the first 19 days of the rat's pregnancy. It shows the following: Necrosis of hepatic tissue (O), expansion of sinusoids (Sw), and bleeding into hepatic tissue (B) (H & E -stain, 10x).

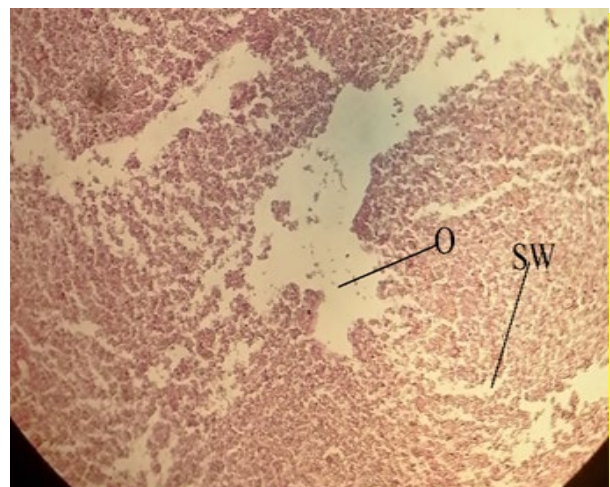

Figure 3: is a cross slice of rat fetus liver that was administered with the spasmine medication for 19 days during gestation It shows: Destruction of the wall of the central vein (D), expansion of the sinusoids (Sw), congestion into the hepatic tissue (B), and necrosis of the hepatic tissue (O) (H & E- stain, 10x).

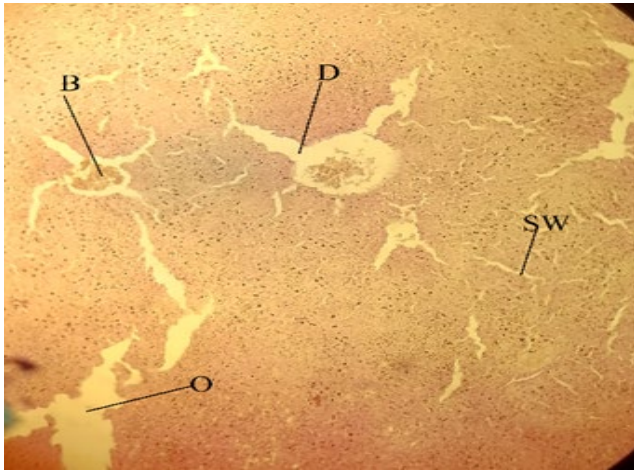


Figure 4: is a cross slice of rat fetus liver that was administered with the spasminic medication for 19 days during gestation. It shows: A breakdown in the fundamental architecture of the hepatic tissue, Widening of sinusoids (Sw) and necrosis of liver tissue (O) (H & E - stain, 10x).

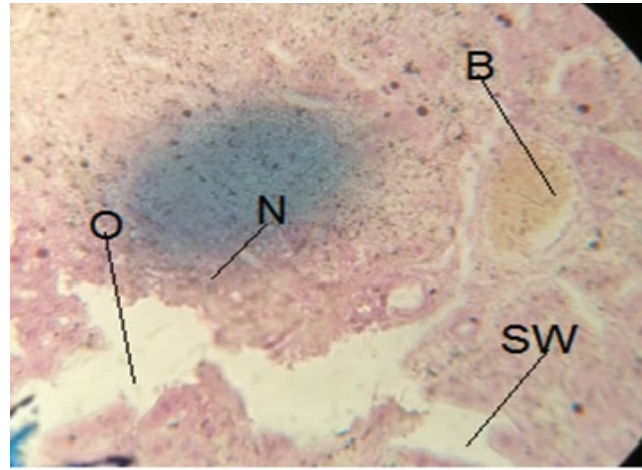


Figure 7: is a cross slice of a rat fetus liver that was administered with the spasminic medication for the first 19 days of gestation. The following may be seen in it: Hepatocyte necrosis (N), sinusoids broadening (SW), necrosis into hepatic tissue (O), and congestion into central vein (B) (H & E - stain, 40X).

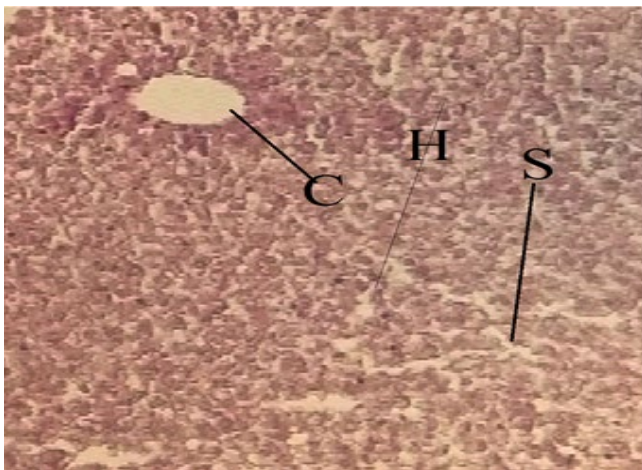


Figure 5: is a cross slice of rat fetus liver from the control group at 19 days' gestation. It shows: Normal structure of hepatic tissue, showing the central vein (C), sinusoids (S), and hepatic cells (H) (H & E- stain, 40X).

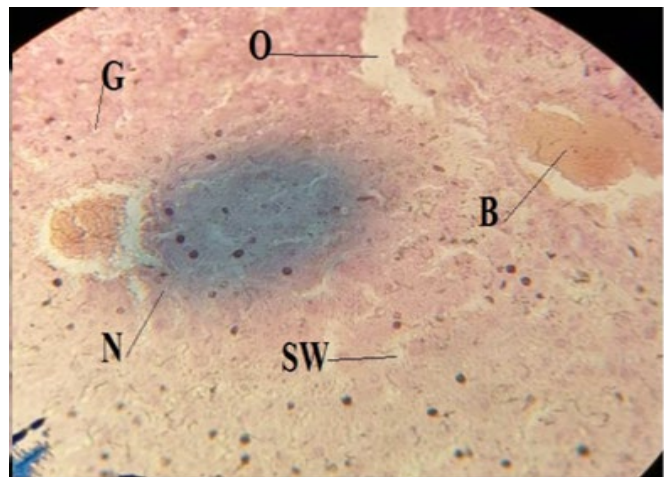


Figure 8: is a cross slice of a rat fetus liver that was administered with the spasminic medication for the first 19 days of gestation. The following may be seen in it: Hepatocyte necrosis (N), sinusoids broadening (SW), necrosis into hepatic tissue (O), and congestion into central vein (B) (H & E - stain, 40X).

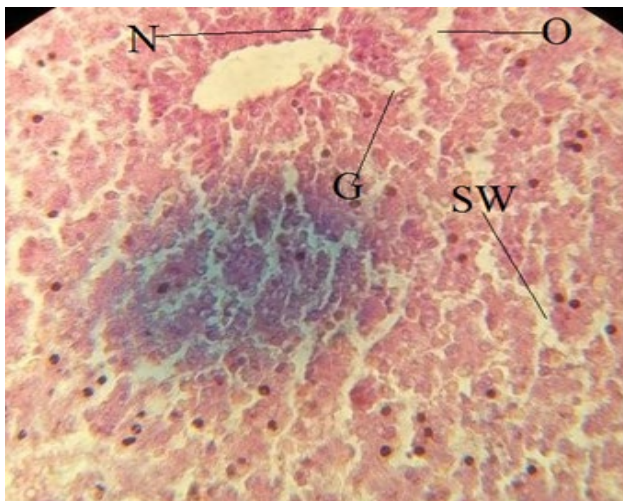


Figure 6: is a cross slice of a rat fetus liver that was administered with the spasminic medication for the first 19 days of the mother's pregnancy. It shows: hepatocyte necrosis (N), hepatocyte degeneration (G), sinusoids expanding (SW), and necrosis into hepatic tissue (O) (H & E - stain, 40X).

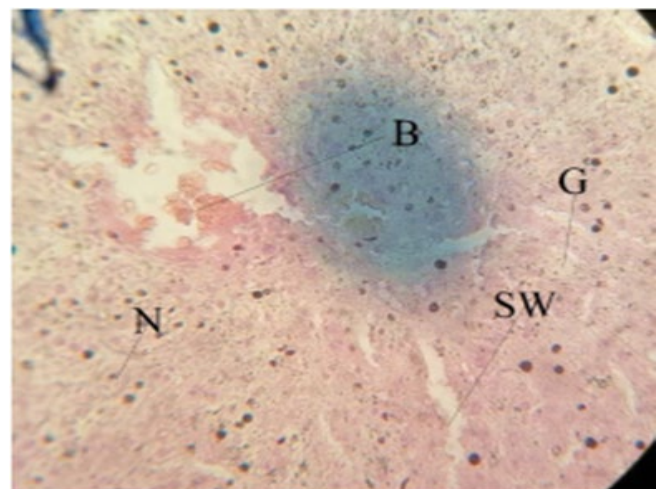


Figure 9: is a cross slice of a rat fetus liver that was administered with the spasminic medication for the first 19 days of the mother's pregnancy. It shows hepatocyte necrosis (N), hepatocyte degeneration (G), sinusoids expanding (SW), and congestion into the central vein (B) (H & E -stain, 40X).

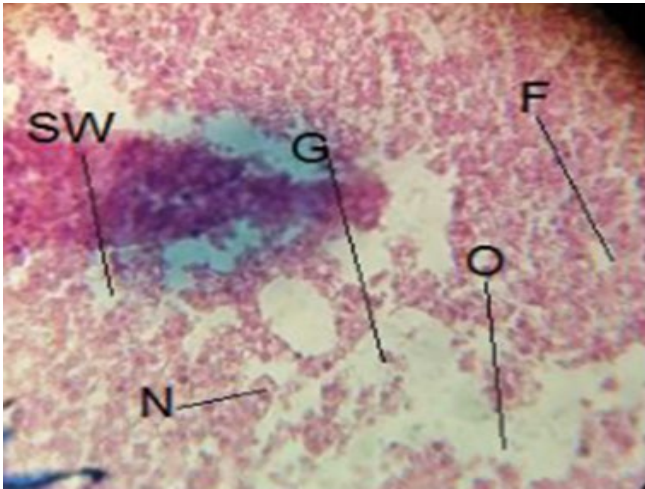


Figure 10: is a cross slice of rat fetus liver that was administered with the spasmine medication for the first 19 days of the mother's pregnancy. It shows the following: Hepatocyte necrosis (N), hepatocyte degeneration (G), sinusoids expanding (SW), necrosis into hepatic tissue (O), and inflammatory cell infiltration (F) (H & E-stain, 40X).

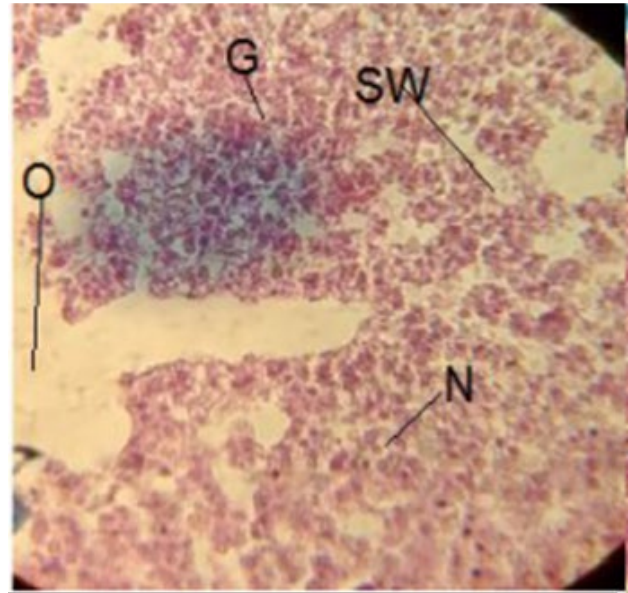


Figure 13: is a cross slice of rat fetus liver that was administered with the spasmine medication for the first 19 days of the rat's pregnancy. What can be seen in this image is the loss of the overall structure of the hepatic tissue. Necrosis into hepatic tissue (O), hepatocyte necrosis (N), hepatocyte degeneration (G), and sinusoids expanding (SW) (H & E -stain, 40x).

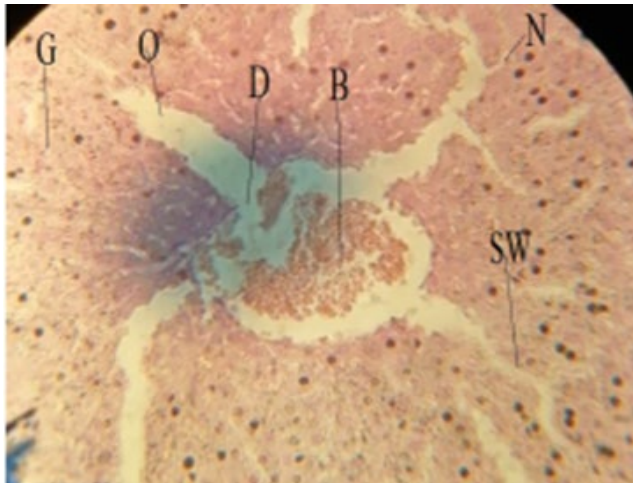


Figure 11: is a cross slice of a rat fetus liver that was administered with the spasmine medication for the first 19 days of the mother's pregnancy. It shows: destruction of central vein wall (D), hepatocyte necrosis (N), hepatocyte degeneration (G), sinusoids widening (SW), necrosis into the hepatic tissue (O), and congestion into the central vein (B) (H & E -stain, 40X).

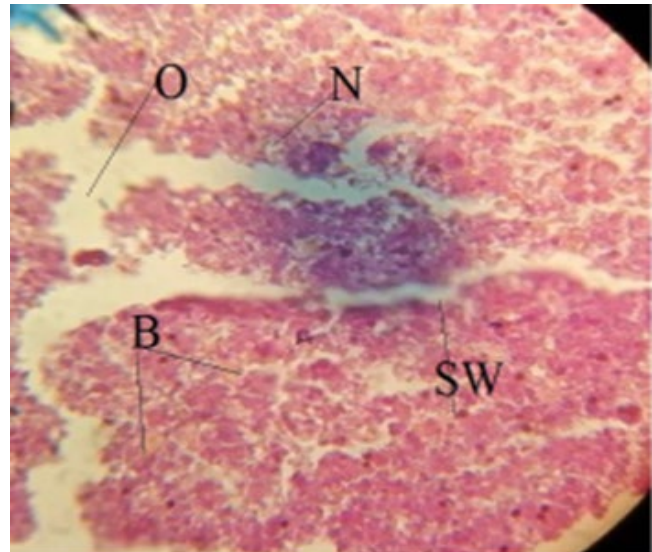


Figure 14: is a cross slice of an of rat fetus liver that was administered with the spasmine medication for the first 19 days of gestation. It shows: A breakdown in the fundamental architecture of the liver's tissue: Hepatocyte necrosis (N), sinusoids broadening (SW), necrosis into hepatic tissue (O), and bleeding into hepatic tissue (B) (H & E -stain, 40x).

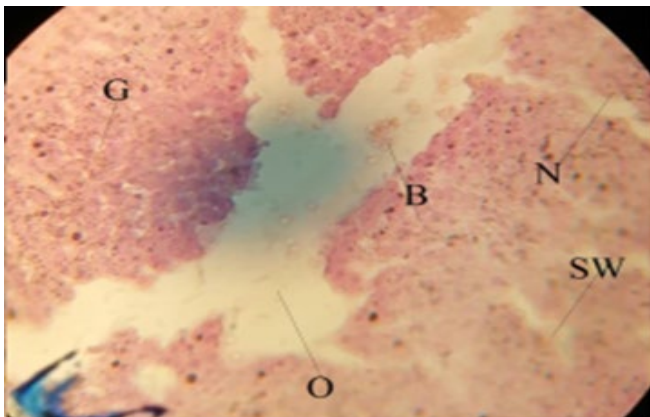


Figure 12: is a cross slice of a rat fetus liver that was administered with the spasmine medication for the first 19 days of the mother's pregnancy. It shows: hepatocyte necrosis (N), hepatocyte degeneration (G), sinusoids expanding (SW), necrosis into hepatic tissue (O), and bleeding (B) (H & E- stain, 40X).

Results of pregnant rat livers

Table 2: Spasmine Medication Effects On pregnant rats Liver Weights During 19th Day of Gestation.

Treatments	Liver weights of pregnant rats(g) M±SE
Control Group(G1)	8.25±0.01
Spasmin Drug Treated Group(G2)	7.50±0.04 &
Least Difference(LSD)	Significant 0.20

&: The Significant differences of administered group with control group at (P<0.05).

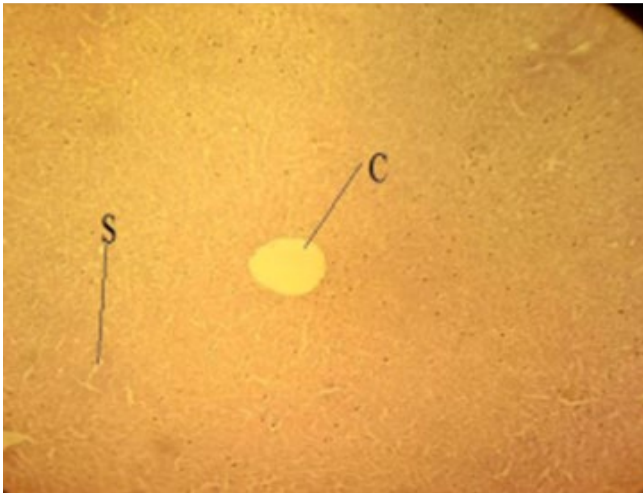


Figure 15: It shows a cross slice of the liver of a pregnant rat animal that was part of the control group during the 19th day of gestation: Normal structure of hepatic tissue, showing sinusoids (S), central vein (C) (H & E -stain, 10x).

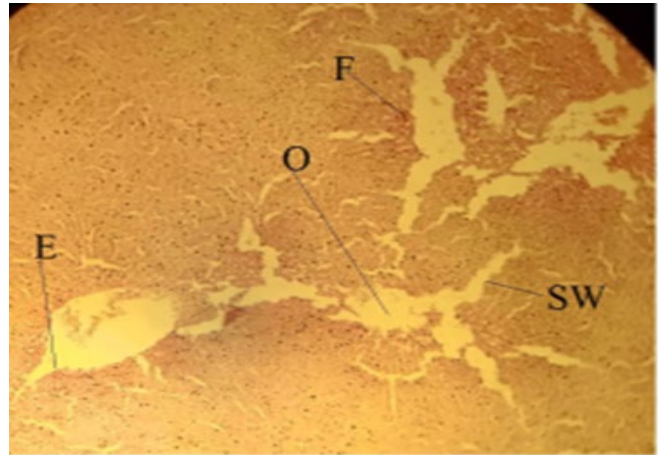


Figure 18: It shows a cross slice of a pregnant rat animal liver that was part of a group that was given the spasmine medication for the first 19 days of the rat's pregnancy. Congestion in the central vein (B) as a result of necrosis in the hepatic tissue (O) and destruction of the central vein wall (D) (H & E -stain, 10x).

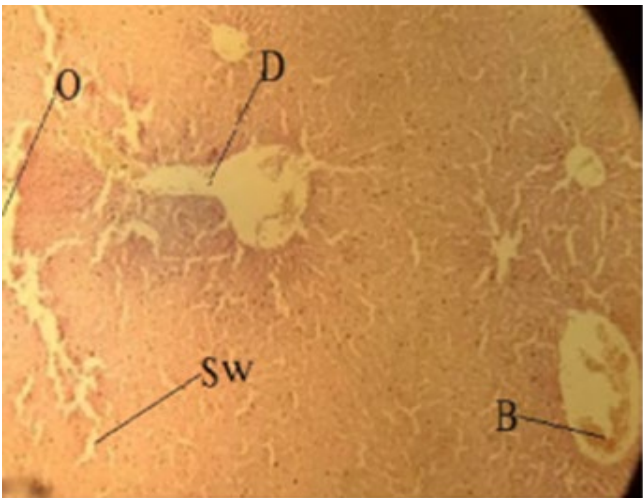


Figure 16: It shows a cross slice of a pregnant rat animal liver that was part of a group that was given the spasmine medication for the first 19 days of the rat's pregnancy: Destruction of the wall of the central vein (D), sinusoids widening (Sw), necrosis in hepatic tissue (O), and congestion in the central vein (B) (H & E -stain, 10x).

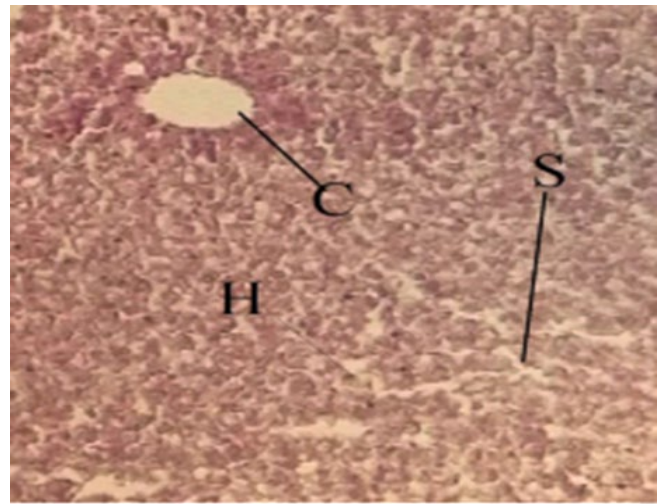


Figure 19: The normal arrangement of hepatic tissue (H), central vein (C), sinuses (S), and hepatic cells (H) are all visible in this cross slice of the liver of a pregnant rat animal from control group during gestation for 19 days (H & E -stain, 40X).

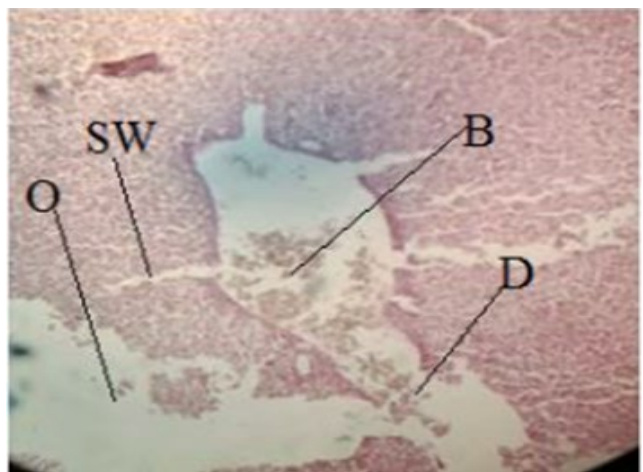


Figure 17: It shows a cross slice of the liver of a pregnant rat animal that was part of a group that was given the spasmine medication for the first 19 days of the rat's pregnancy. Inflammatory cell infiltration (F), necrosis in hepatic tissue (O), expansion of the central vein (E) (H & E -stain, 10x).

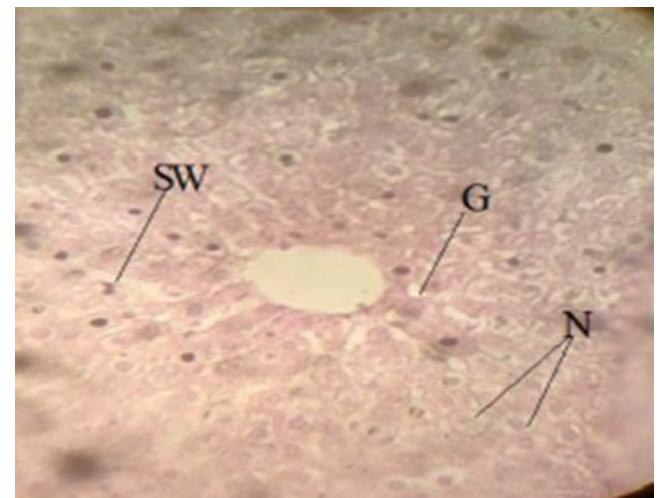


Figure 20: It shows a cross slice of a pregnant rat animal liver that was part of a group that was given the spasmine medication for the first 19 days of the rat's pregnancy: Hepatocyte necrosis (N), hepatocyte degeneration (G), and sinusoids broadening (SW) (H & E -stain, 40X).

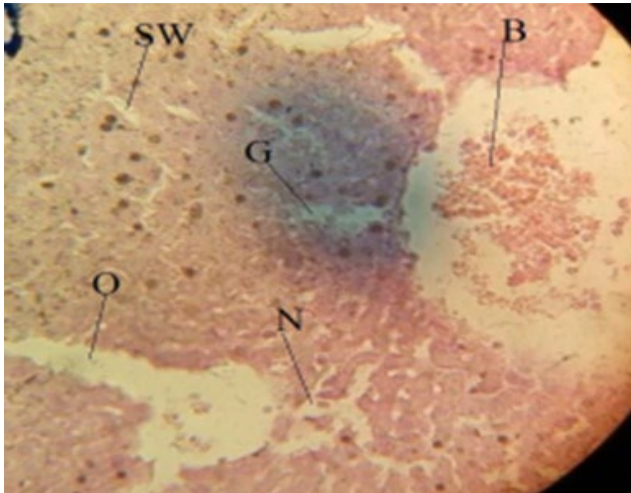


Figure 21: It shows a cross slice of a pregnant rat animal liver that was part of a group that was given the spasmine medication for the first 19 days of the rat's pregnancy: hepatocyte necrosis (N), destruction of the central vein (D), sinusoids expanding (SW), and congestion into the central vein (B) (H & E -stain, 40X).

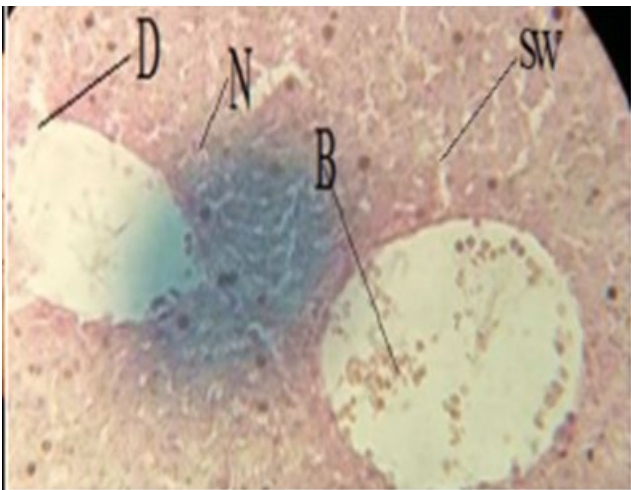


Figure 22: It shows a cross slice of a pregnant rat animal liver that was part of a group that was given the spasmine medication for the first 19 days of the rat's pregnancy: Necrosis into hepatic tissue (O), congestion in the central vein (B), Hepatocyte necrosis (N), sinusoids widening (SW), hepatocyte necrosis (N), and sinusoids widening (SW) (H & E -stain, 40X).

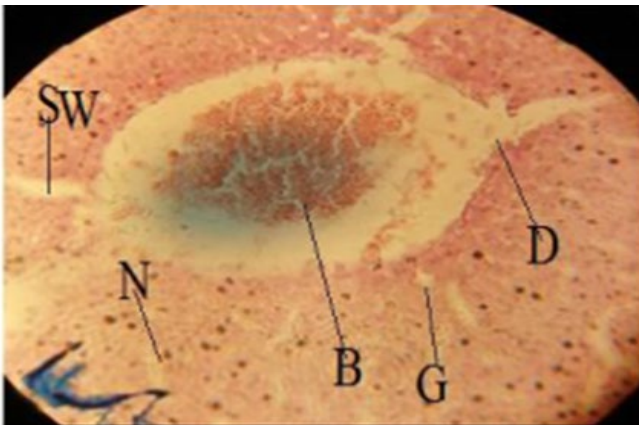


Figure 23: It shows a cross slice of a pregnant rat animal liver that was part of a group that was given the spasmine medication for the first 19 days of the rat's pregnancy: The destruction of the wall of the central vein (D), Necrosis of hepatocytes (N), necrosis of hepatic tissue (O), and congestion in the central vein (B) (H & E -stain, 40X).

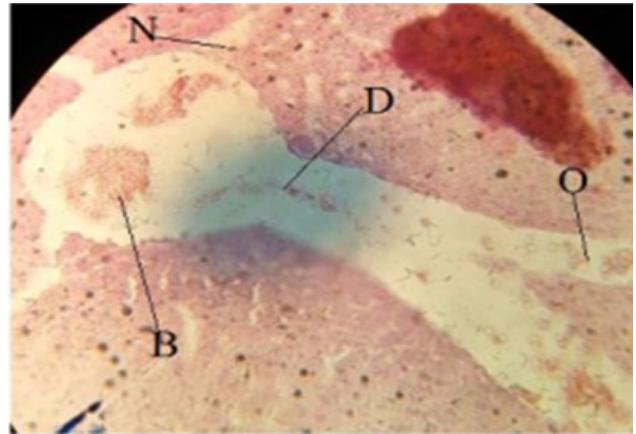


Figure 24: It shows a cross slice of a pregnant rat animal liver that was part of a group that was given the spasmine medication for the first 19 days of the rat's pregnancy: Abnormalities hepatocyte necrosis (N), hepatocyte degeneration (G), sinusoids broadening (SW), and congestion into the central vein (B) (H & E -stain, 40X).

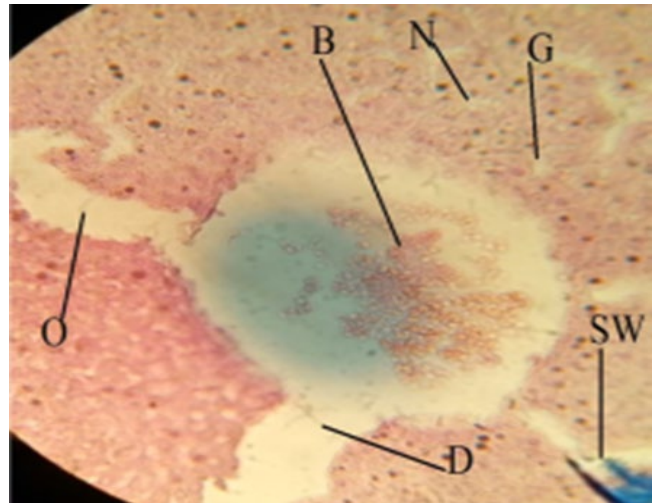


Figure 25: It shows a cross slice of a pregnant rat animal liver that was part of a group that was given the spasmine medication for the first 19 days of the rat's pregnancy: Expansion and destruction of the central vein wall (D), hepatocyte necrosis (N), hepatocyte degeneration (G), necrosis into hepatic tissue (O), sinusoids expanding (SW), and congestion into hepatic vessels (B), Expansion and destruction of the central vein wall (D)(H & E -stain, 40X).

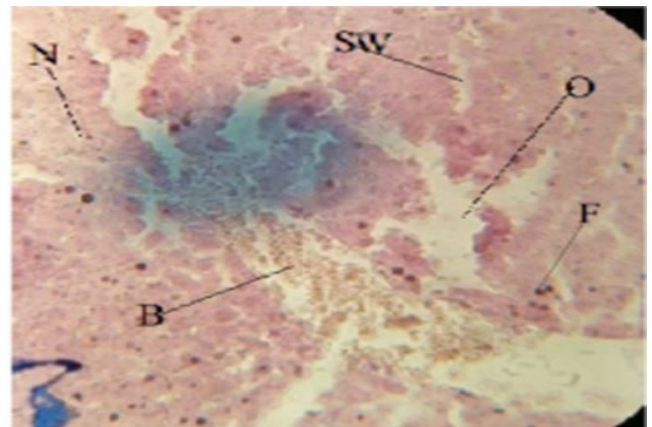


Figure 26: It shows a cross slice of a pregnant rat animal liver that was part of a group that was given the spasmine medication for the first 19 days of the rat's pregnancy: Hepatocyte necrosis (N), necrosis into hepatic tissue (O), sinusoids expanding (SW), congestion into hepatic vessel (B), and inflammatory cell infiltration (F) (H & E -stain, 40X).

References

1. S. S. Abdulhady and K. M. H. Ibrahim, "Preparation and evaluation of mebeverine hydrochloride as mucoadhesive buccal tablet for local anesthesia," *Tropical Journal of Pharmaceutical Research*, vol. 16, no. 8, pp. 1805-1812, 2017.
2. J. A. Ford, "Nonmedical prescription drug use and delinquency: An analysis with a national sample," *Journal of Drug Issues*, vol. 38, no. 2, pp. 493-516, 2008.
3. I. N. Stankovic and D. Colak, "Prenatal drugs and their effects on the developing brain: insights from three-dimensional human organoids," *Frontiers in Neuroscience*, vol. 16, p. 848648, 2022.
4. R. K. Creasy and R. Resnik, *Creasy and Resnik's Maternal-fetal Medicine | Maternal-fetal Medicine*. Elsevier Saunders, 2014.
5. E. Çiçek, D. Avşar, H. Yeldan, and M. Manaşırılı, "Otoliths atlas of 77 fish species from the Iskenderun Bay, Northeastern Mediterranean Sea," *FishTaxa*, vol. 19, pp. 9-55, 2021.
6. A. Annaházi, R. Róka, A. Rosztóczy, and T. Wittmann, "Role of antispasmodics in the treatment of irritable bowel syndrome," *World journal of gastroenterology: WJG*, vol. 20, no. 20, p. 6031, 2014.
7. J. Daniluk, E. Malecka-Wojcieszko, B. Skrzydło-Radomska, and G. Ryzewska, "The efficacy of mebeverine in the treatment of irritable bowel syndrome—A systematic review," *Journal of clinical medicine*, vol. 11, no. 4, p. 1044, 2022.
8. M. T. De Silva and S. R. Jang, "Competitive exclusion and coexistence in a Lotka–Volterra competition model with Allee effects and stocking," *Letters in Biomathematics*, 2015, doi: <https://doi.org/10.30707/LiB2.1DeSilva>.
9. H. K. Ensslin, H. H. Maurer, E. Gouzoulis, L. Hermlé, and K.-A. Kovar, "Metabolism of racemic 3, 4-methylenedioxyethylamphetamine in humans. Isolation, identification, quantification, and synthesis of urinary metabolites," *Drug metabolism and disposition*, vol. 24, no. 8, pp. 813-820, 1996.
10. S. M. Abdel-Hamid, S. E. Abdel-Hady, A.-H. A. El-Shamy, and H. F. El-Dessouky, "A novel formulation for mebeverine hydrochloride," *Drug development and industrial pharmacy*, vol. 33, no. 10, pp. 1078-1089, 2007.
11. K. Hatami *et al.*, "Comparing the efficacy of Cumin Sofouf with mebeverine on irritable bowel syndrome severity and quality of life: a double-blind randomized clinical trial," *Crescent Journal of Medical & Biological Sciences*, vol. 7, no. 2, 2020.
12. J. Gilbody, C. Fletcher, I. Hughes, and S. Kidman, "Comparison of two different formulations of mebeverine hydrochloride in irritable bowel syndrome," *International journal of clinical practice*, vol. 54, no. 7, pp. 461-464, 2000.
13. W. Schaffstein, M. Panijel, and K. Luettecke, "Comparative safety and efficacy of trimebutine versus mebeverine in the treatment of irritable bowel syndrome: a multicenter double-blind study," *Current therapeutic research*, vol. 47, no. 1, pp. 136-145, 1990.
14. S. Elliott and V. Burgess, "Investigative implications of the instability and metabolism of mebeverine," *Journal of analytical toxicology*, vol. 30, no. 2, pp. 91-97, 2006.
15. A. A. Soares Costa *et al.*, "Lung cancer biomarkers. A literature review," *Jornal Brasileiro de Patologia e Medicina Laboratorial*, vol. 58, 2022, doi: 10.1900/JBPML.2022.58.415.
16. B. Rangel-Colmenero *et al.*, "BEHAVIOUR OF CHOLINESTERASES AFTER FATIGUE CONDITIONS IN ENDURANCE RUNNERS," *Revista Internacional de Medicina y Ciencias de la Actividad Física y del Deporte*, vol. 22, no. 85, 2022.
17. Z. C. Pope, D. J. Barr-Anderson, B. A. Lewis, M. A. Pereira, and Z. Gao, "Use of wearable technology and social media to improve physical activity and dietary behaviors among college students: A 12-week randomized pilot study," *International Journal of Environmental Research and Public Health*, vol. 16, no. 19, p. 3579, 2019.
18. M. BILECENOGLU and T. ÇELİK, "Easternmost occurrence of *Didogobius schlieveni* Miller, 1993 (Gobiidae) in the Mediterranean Sea," *FishTaxa*, vol. 19, pp. 1-4, 2021.
19. E. S. Hafez, "Reproductive and breeding techniques for laboratory animals," *Lea and Febiger, Philadelphia, PA*, 1970.
20. J. D. Bancroft, C. Layton, and S. K. Suvarna, *Bancroft's theory and practice of histological techniques*. Churchill Livingstone Elsevier, 2013.
21. C. Palmieri and R. Conger, "Teratogenic potential of the newer antiepileptic drugs: what is known and how should this influence prescribing?," *CNS drugs*, vol. 16, pp. 755-764, 2002.
22. Y. Ozsurekci and K. Aykac, "Oxidative stress related diseases in newborns," *Oxidative medicine and cellular longevity*, vol. 2016, 2016.
23. M. Amiri, "Oxidative stress and free radicals in liver and kidney diseases; an updated short-review," *Journal of Nephropathology*, vol. 7, no. 3, 2018.
24. B. A. Freeman and J. D. Crapo, "Biology of disease: free radicals and tissue injury," *Laboratory investigation; a journal of technical methods and pathology*, vol. 47, no. 5, pp. 412-426, 1982.
25. G. G. Oliveira, R. P. Barcelos, and L. d. O. Siqueira, "Analysis of correlation of glucose dosage by glycosimeter, laboratory dosage and artificial intelligence equipment," *Jornal Brasileiro de Patologia e Medicina Laboratorial*, vol. 58, 2022, doi: 10.1900/JBPML.2022.58.414.
26. S. Donovan *et al.*, "QUBES: a community focused on supporting teaching and learning in quantitative biology," *Letters in Biomathematics*, vol. 2, no. 1, pp. 46-55, 2015, doi: <https://doi.org/10.30707/LiB2.1Donovan>.
27. R. Al-Naemi, Q. Abdullah, and S. Ibrahim, "Impact of oxidative stress on pregnancy outcome in albino rats," *Iraqi Journal of Veterinary Sciences*, vol. 26, no. 2, pp. 93-99, 2012.
28. S. Elshama, M. Abdalla, and A. Mohamed, "Role of Natural antioxidants in treatment of toxicity," *Journal of Toxicology Analysis*, vol. 1, pp. 3-7, 2018.
29. D. Del Rio, A. J. Stewart, and N. Pellegrini, "A review of recent studies on malondialdehyde as toxic molecule and biological marker of oxidative stress," *Nutrition, metabolism and cardiovascular diseases*, vol. 15, no. 4, pp. 316-328, 2005.
30. J. Gamonales, J. Muñoz-Jiménez, K. León, and S. Ibáñez, "EFFECTIVENESS OF THE LAUNCH AT FA5 FOR BLIND PERSONS IN 2016 PARALYMPIC GAMES," *Revista Internacional de Medicina y Ciencias de La Actividad Física y Del Deporte*, vol. 19, no. 76, 2019.