

Access this article online

Quick Response Code:



Website:

www.carcinogenesis.com

DOI:

10.4103/jcar.jcar.22.02.15

Histological Effects of Diclofenac in the Kidneys of Male Rats and the Role of the Aqueous Extract of Moringa Oleifera Seeds in the Protection

Nagham Saleh Sahib Hadi ¹, Dalal Abdel-Hussein Kadhim AL-Essawi ¹

Abstract

The study aimed to assess the protective effect of Moringa oleifera seed extract against diclofenac-induced kidney damage in male albino rats. Thirty adult male rats were divided into six groups and treated for 35 days. Group 1 was the control, group 2 received diclofenac (100 mg/kg), groups 3 and 4 were treated with Moringa oleifera seed extract at two concentrations (400 mg/kg and 600 mg/kg), and groups 5 and 6 received Moringa oleifera seed extract at the same concentrations along with diclofenac (100 mg/kg). Kidney histology was examined after sacrifice. Results showed that the control group had normal kidney structures. The diclofenac-treated group exhibited kidney histological changes, including glomerular shrinkage, Bowman's space widening, cell necrosis in urinary tubules, tissue necrosis with hemorrhage, and inflammatory cell infiltration. However, groups treated with Moringa oleifera seed extract (at 450 mg/kg and 600 mg/kg) showed normal kidney tissue with no abnormalities. In groups treated with both Moringa oleifera seed extract and diclofenac, some minor changes were observed, such as slight widening of Bowman's space, minimal necrosis in urinary tubule cells, and slight bleeding in urinary tissue.

Keywords:

Diclofenac, Moringa Oleifera, Kidneys, Negative Histological Effects.

Introduction

Moringa oleifera plant is one of the important medicinal plants that has been used as a treatment for many diseases as a substitute for many drugs and medical medicines ^[1]. The Moringa oleifera plant has been used since ancient times because it contains organic substances, amino acids, phenols, carotenoids, flavonoids, isothiocyanates, enzymes, glucosins, minerals, sterols and tannins which are substances responsible for the formation of antioxidants ^[2]. In the human body, these substances contain many properties such as hepatoprotective properties, antioxidants, and antimicrobials ^[3]. In modern times, Moringa oleifera has entered medical laboratories as a healthy nutritional supplement to reduce malnutrition ^[4, 5]. It has also been used in the treatment of cardiovascular diseases, antihypertensives,

protection against diabetes, cancer, oxidation, tumor treatment, spleen enlargement, infections, convulsions, depression, germs and fungi and diuretic ^[6]. Diclofenac drug is an anti-inflammatory drug that belongs to non-steroidal anti-inflammatory drugs. It works by reducing the production of prostocladin and oxidation enzymes that cause inflammation and pain in the body. It is one of the most widely used drugs in all parts of the world ^[7]. Pain-relieving anti-inflammatory drugs are among the most common medications that help relieve pain quickly, and they can be used without a prescription to remove fever and relieve pain ^[8] and used to treat mild to moderate pain, rheumatoid arthritis, spondylolisthesis, eye infections, fever, gout, and migraine ^[9]. Serious side effects of diclofenac include cardiovascular thrombosis, heart failure, high blood pressure, sore throat, burning eyes, skin rash, exfoliative dermatitis, and idiopathic use of many analgesics.

This is an open-access journal, and articles are distributed under the terms of the Creative Commons Attribution-Non-Commercial-Share Alike 4.0 License, which allows others to remix, tweak, and build upon the work non-commercially, as long as appropriate credit is given and the new creations are licensed under the identical terms.

For reprints contact: editor@carcinogenesis.com

How to cite this article: Hadi N S S, AL-Essawi D A H K. Histological Effects of Diclofenac in the Kidneys of Male Rats and the Role of the Aqueous Extract of Moringa Oleifera Seeds in the Protection. J Carcinog 2023;22(2):120 -125

¹ Biology Department-
Education for Girls Faculty-
Kufa University Iraq.

Address for correspondence:

Nagham Saleh Sahib
Hadi,
Biology Department- Education
for Girls Faculty- Kufa
University Iraq.

E-mail:

dalala.alesawi@uokufa.edu.
iq

Submitted: 19-Jan-2023

Revised: 09-Aug-2023

Accepted: 29-Sep-2023

Published: 19-Oct-2023

Renal and heart failure leading to death even at the treated dose^[10]. The mechanism of action of diclofenac is summarized in its ability to inhibit the enzyme cyclooxygenase COX, which helps in the formation of chemicals known as prostaglandins that cause pain and inflammation, and when preventing the formation of this substance leads to a reduction in pain and inflammation^[11], as diclofenac inhibits the manufacture of cyclooxygenase 2 enzyme, and thus reduces the incidence of infection. With regard to the side effects of the digestive system, compared to both indomethacin and aspirin, the effectiveness of a single dose of diclofenac (6 to 8 hours) is much longer than the half-life of the drug, which is considered short. The reason for this can be attributed to the fact that diclofenac persists for more than 11 hours in the synovial fluid^[12]. Diclofenac drug inhibits generation of cyclooxygenase-1 and -2, these the enzymes responsible for the production of prostaglandins (PG) and these molecules have broad activity in pain and inflammation, and inhibition of their production is the common mechanism linking each effect of diclofenac^[13].

Materials and Methods

Experimental Animals

In this study, 30 adult male laboratory white rats were used whose had an average weight of (220 g) and an average age of (3) months and they were raised in the animal house of the College of Science / University of Kufa for the period from 11/2022 to the beginning of 2/2023 and the animals were placed in special plastic cages covered with metal covers and the floor was covered with fine wood sawdust and the cages were cleaned and the floor was constantly replaced and they were sterilized with disinfectants, as well as the continuous cleaning of the irrigation channels and the shelter room. All experimental animals were subjected to appropriate laboratory conditions in terms of temperature (20 to 25) C, lighting material (12) hours per day, and good ventilation. The animals were also provided with water and diet freely throughout the research period and the rats were left to adapt for two weeks before conducting the experiment and make sure that it is free of diseases.

Preparation Moringa Oleifera Aqueous Extract

The seeds of the *Moringa oleifera* plant were purchased from shops selling herbs and seeds in the province of Najaf, and they were classified by professors specialized in plant classification at the University of Kufa. With a laboratory medicinal herb grinder until a fine powder is obtained, 20 g of dry powder was taken and mixed with 400 ml of hot distilled water using an electric mixer, and left for 24 hours at room temperature, then the mixture was filtered using layers of medical gauze for the purpose of getting rid of plankton and then centrifuged at 3000 rpm for 10 minutes. The extract was filtered using (Whatman No.101) filter papers to obtain a clear

solution, then dried in the oven after placing it in sterile glass dishes and sealed until use^[14].

Paraperation the Dose of Diclofenac

Diclofenac drug was obtained in the form of tablets (pills) at a dose of 100 mg/kg (the dose used in humans) from pharmacies in Najaf Province (Micro Labs Limited company-India), and the concentration of the drug dose required in the current study, and the animals were dosed according to body weight^[15].

Experience Design

30 male rat animals were distributed into six groups with only five male rats per group. The first group which represented the control group was given distilled water, while the second group was dosed with diclofenac at a concentration of 100 mg/kg of body weight, while the third group was dosed with hot aqueous extract of plant seeds *Moringa oleifera* at a concentration of 450 mg/kg of body weight^[16]. While the fourth group was dosed with the aqueous extract of *Moringa oleifera* seeds at a concentration of 600 mg/kg of body weight, while the fifth group was dosed daily with the hot aqueous extract of *Moringa oleifera* seeds at a concentration of 450 mg/kg two hours before they were given diclofenac at a concentration of 100 mg/kg of body weight and the sixth group was dosed daily with the hot aqueous extract of the seeds of *Moringa oleifera* at a concentration of 600 mg/kg two hours before administering diclofenac at a concentration of 100 mg/kg of body weight^[17].

- Animal Dissection and Tissue Collection

Animals are dissected after anesthesia with chlorfoam by making an incision in the abdominal cavity using scissors from the bottom towards the heart and the kidneys were removed after removing the fatty tissue surrounding it. They were dried by placing them on filter paper, then the organs were placed in formalin at a concentration of 10 ml in plastic containers and labeled after cutting them transversely for ease of preservation and to ensure that the fixed material reached them.

Histological Preparations

Histological sections were prepared according to the method of Bancroft and Stevens^[18].

-Microscopic Examination and Photomicrography

The slides were examined to determine changes in the histological sections using a light microscope of the type (Olympus CX21) with a magnification of 40X, and then the slides were photographed which is^[19, 20] equipped with a high-resolution digital camera connected to a computer.

Results and Discussion

The results of the histological examination of the kidney in control group showed that normal structure of the glomerulus, Bowman capsule, Bowman space, and urinary tubules as in figure (1), while the results of the

histological examination of the kidney in the group treated with diclofenac at a concentration of (100) mg / kg of body weight showed histological changes represented by shrinkage and atrophy of the renal glomerulus, widening of the Bowman's space, necrosis of the cells lining the urinary tubules, necrosis of the urinary tissue with hemorrhage and infiltration of inflammatory cells as shown in the figures (3,2). While the results of the microscopic examination of the kidney tissue of the group treated with the aqueous extract of the seeds of the *Moringa oleifera* plant at a concentration of (450) mg/kg of body weight as well as the group treated with aqueous extract of *Moringa oleifera* seeds at a concentration of (600) mg/kg of body weight, as shown in figures (4,5) and (6,7) respectively, and the composition of the kidney tissue was normal and no abnormal changes were observed in it compared to the control group, also, the composition of kidney tissue was normal or close to normal in a group of rats treated with aqueous extract of *Moringa oleifera* plant seeds at two concentrations (450) mg/kg and (600) mg/kg + diclofenac at a concentration of (100) mg/kg of body weight, as it is noted normal glomeruli and normal urinary tubules with little widening in Bowman's space and little necrosis in some cells lining the urinary tubules. In addition to little bleeding in the urinary tissue, as shown in figures (8,9,10,11) respectively, the reasons for these results may be back to diclofenac drug inhibits the production of prostaglandins which lead to shrinkage of the renal glomerulus, widening of the Bowman's space, necrosis of the urothelial tissue, necrosis of the cells lining the urinary tubules with hemorrhage between the urinary tubules, destruction of the urothelial cells and degeneration of the glomerulus and atrophy in the renal glomerulus [21] and thus causes disruption of glomerular filtration, as well as the destruction of tubular functionality of the kidney and renal metabolism [22]. The dosing of diclofenac in male rats stimulates severe inflammation in the renal tissue [23], or the cause of damage to the renal tissue may be attributed to the fact that the use of diclofenac and other non-steroidal anti-inflammatory drugs [24] causes increased Oxidative stress and this is shown by the current study and thus causes the production and synthesis of free radicals responsible for the pathological changes that cause tissue breakdown and that the inhibition of these cells is an important source for the generation of oxygen free radicals by the mitochondria which is an important source in the generation of free radicals, as the drug diclofenac causes lack of ischemia blood vessels in the kidney which leads to the destruction and damage to the tissues of the urinary system and that the use of drugs (NSAIDS)[25] and It causes complications and side effects such as hepatotoxicity [26] nephrotoxicity which causes an inhibitory effect on the COX enzymes responsible for the synthesis of urinary prostaglandins [27], while the results of histological examination of histological sections in the two groups treated with the aqueous extract of the seeds of the *Moringa oleifera* plant in two concentrations (450 and 600) mg / kg, not affecting the kidney tissue and

maintaining the normal size of the glomerulus and urinary tubules and this leads to maintaining the natural balance of oxidation preventing damage and protecting cellular membranes [28] as confirmed by studies conducted by Akinrinde et al [29] and as shown by our current study, while kidney tissue in the group treated with aqueous extract of *Moringa oleifera* plant seeds at two concentrations (450 and 600) mg/kg + diclofenac at a concentration of (100) mg/kg of body weight, which showed that the histological structure of the kidney was normal or close to normal. With a little necrosis in the renal cells, this may be due to the fact that the *Moringa oleifera* plant acts as a protective role in protecting the kidney tissue from the drug diclofenac, as it prevents necrosis in the renal cells, and protects the kidney tissue because the *Moringa oleifera* plant contains flavonoids, and it has anti-inflammatory activity to oxidation [30] and this explains the role of the *Moringa oleifera* plant as an antioxidant which causes improvement in kidney and tissue functions, and a return to normal with the kidneys, as well as the role of the aqueous extract of *Moringa oleifera* seeds in reducing harmful nephrotoxic effects which works as a natural substance to mitigate changes in kidney function and damage [31]. The oxidative stress caused by the drug in the tissues of the kidney, and it also works to reduce the oxidative stress which occurs during the tissues of the kidney and curb the free radicals that this extract possesses and reduce the levels of urea and creatinine, and this is what the current study showed, and then increases the glomerular filtration rate [32] and Preserving tissues in a normal state as studies have confirmed that a non-steroidal anti-inflammatory drug such as indomethacin reduces the production of urinary prostaglandins which cause the occurrence of vascular contractions prepared for blood vessels stimulating a lack of blood supply and thus a lack of access to blood and what is in it of O₂ and nutrients to the various tissues causing necrosis and degeneration and destruction of urinary tissue in addition to the oxidative stress caused by this drug which leads to the destruction of urinary tissue [33, 34].

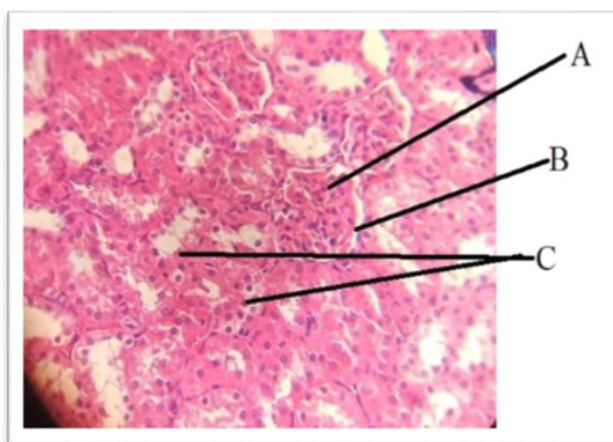


Figure (1): A cross-section of normal male rat kidney tissue in the control group, showing: renal glomerulus (A), Bowman's space (B), urinary tubules (C). (H & E Stain 40X).

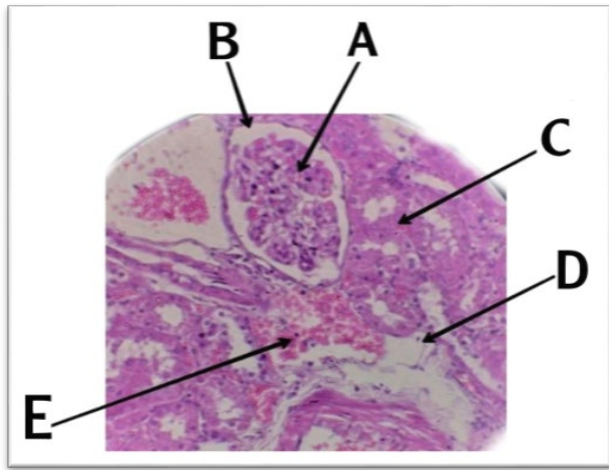


Figure (2): a cross- section of the kidney tissue of a male rat in the group treated with diclofenac at a concentration of (100) mg/kg of body weight, a shrinkage of the renal glomerulus (A), a widening of the Bowman's space (B), and necrosis of the cells lining the tubules (C), necrosis of the urinary tissue (D), and hemorrhage between the urinary tubules (E) (H & E Stain 40X).

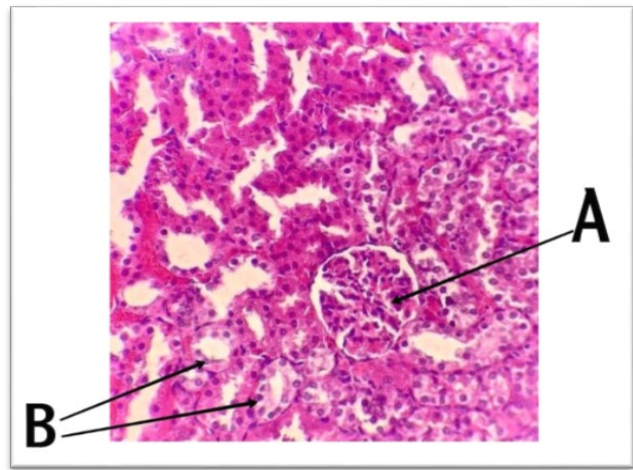


Figure (5): a cross- section of the kidney tissue of a male rat in the group treated with the aqueous extract of Moringa oleifera seeds at a concentration of (450) mg/kg of body weight, showing normal renal glomerulus (A), and normal urinary tubules (B) (H & E Stain 40X).

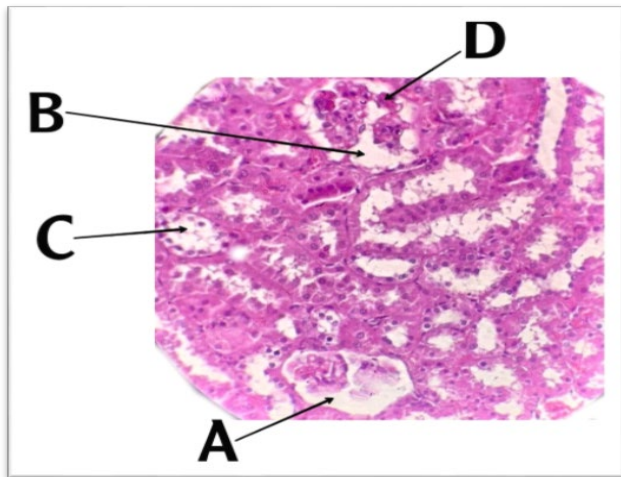


Figure (3): a cross- section of a male rat kidney tissue in the group treated with diclofenac at a concentration of (100) mg/kg of body weight, showing: degeneration of the renal glomerulus (A), widening of Bowman's space (B), and destruction of the lining cells for urinary tubules (C), and inflammatory cell infiltration (D) (H & E Stain 40X).

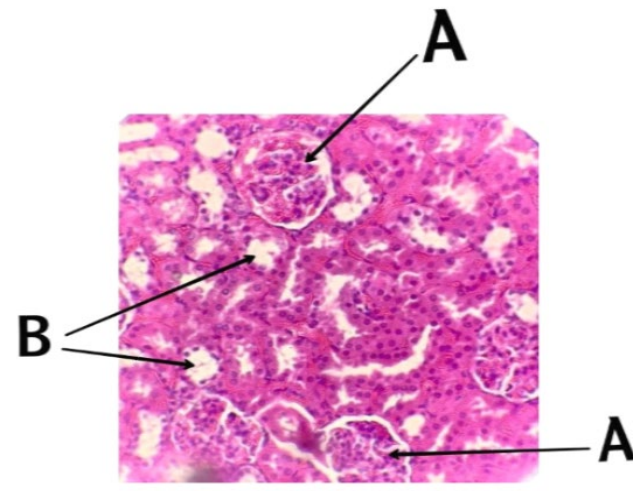


Figure (6): a cross -section of the kidney tissue of a male rat in the group treated with aqueous extract of Moringa oleifera seeds at a concentration of (600) mg/kg of body weight, showing: a normal renal glomeruli (A) and normal urinary tubules (B) (H&E Stain 40X).

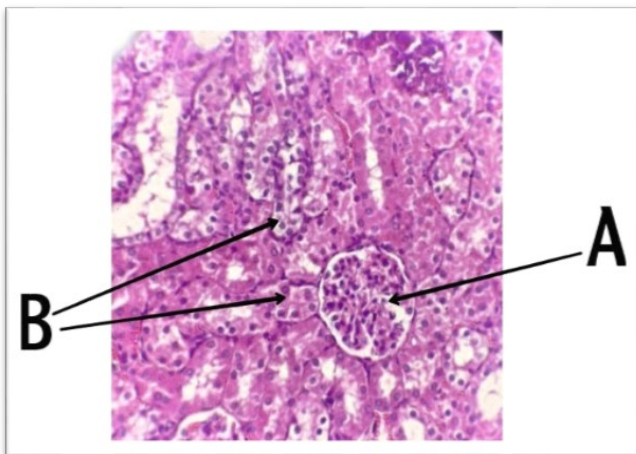


Figure (4): cross- section of kidney tissue of a male rat in the group treated with aqueous extract of Moringa oleifera seeds at a concentration of (450) mg/kg of body weight, as it appears that there are normal renal glomeruli (A) and normal urinary tubules (B). (H&E Stain 40X).

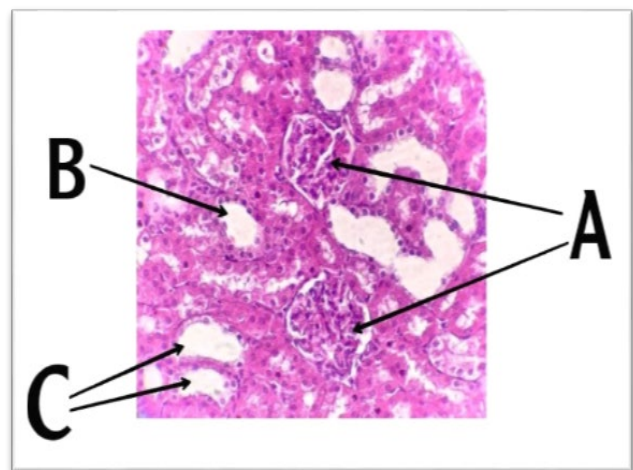


Figure (7): A cross- section of the kidney tissue of a male rat in the group treated with aqueous extract of Moringa oleifera seeds at a concentration of (600) mg/kg of body weight, showing: normal renal glomeruli (A) and normal urinary tubules (B) are noted, and they are dilated (C) Bowman space (H&E Stain 40X).

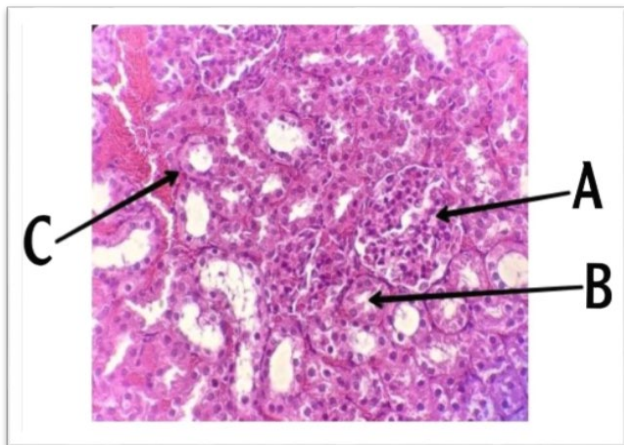


Figure (8): a cross- section of the kidney tissue of a male rat in the group treated with the aqueous extract of *Moringa oleifera* seeds at a concentration of (450) mg/kg with diclofenac at a concentration of (100) mg/kg of body weight, showing: a normal glomerulus. (A), normal urinary tubules (B), and minimal hemorrhage in the urinary tissue (C) (H & E Stain 40X).

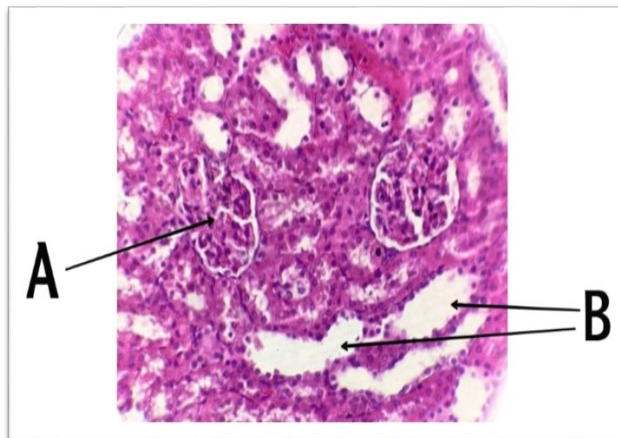


Figure (11): cross- section of kidney tissue of a male rat in the group treated with aqueous extract of *Moringa oleifera* seeds at a concentration of (600) with diclofenac at a concentration of (100) mg/kg of body weight, showing: a normal renal glomeruli (A), and a little dilatation in some urinary tubules (B) (H & E Stain 40X).

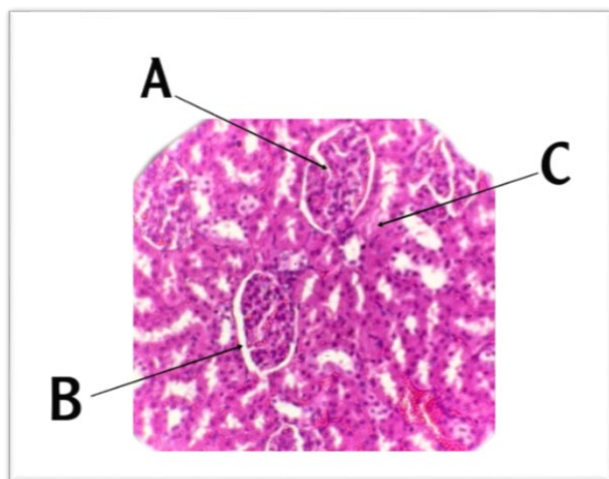


Figure (9): cross- section of kidney tissue of a male rat in the group treated with aqueous extract of *Moringa oleifera* seeds at a concentration of (450) mg/kg with diclofenac at a concentration of (100) mg/kg of body weight, showing: a normal glomerulus (A), a slight widening of the Bowman's space (B), and a slight necrosis in some cells lining the urinary tubules (C) (H & E Stain 40X).

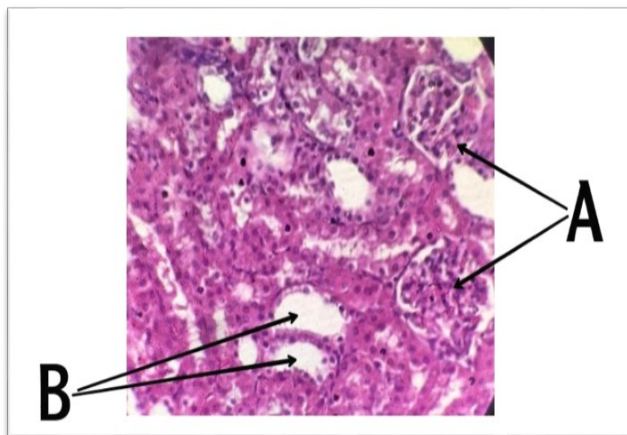


Figure (10): cross-sectional section of kidney tissue of a male rat in the group treated with aqueous extract of *Moringa oleifera* seeds at a concentration of (600) with diclofenac at a concentration of (100) mg/kg of body weight, as it appears that there are normal renal glomeruli (A), and amplitude in Bowman's space (B). (H&E Stain 40X).

Conclusion

It can be concluded from the current study that the aqueous extract of the roots of the *Moringa oleifera* plant had a protective role against the negative histological effects of the kidney stimulated by diclofenac in male rats for a period of 35 days.

References

1. S. Naveed *et al.*, "Prevalence of common mental disorders in South Asia: a systematic review and meta-regression analysis," *Frontiers in psychiatry*, vol. 11, p. 573150, 2020.
2. H. Nhut *et al.*, "Use of *Moringa oleifera* seeds powder as bio-coagulants for the surface water treatment," *International Journal of Environmental Science and Technology*, vol. 18, pp. 2173-2180, 2021.
3. H. M. Abdel-Latif, M. M. Abdel-Daim, M. Shukry, J. Nowosad, and D. Kucharczyk, "Benefits and applications of *Moringa oleifera* as a plant protein source in Aquafeed: A review," *Aquaculture*, vol. 547, p. 737369, 2022.
4. S. Brar *et al.*, "The impact of *Moringa oleifera* leaf supplementation on human and animal nutrition, growth, and milk production: A systematic review," *Phytotherapy Research*, vol. 36, no. 4, pp. 1600-1615, 2022.
5. R. FRICKE, Z. S. RANDALL, and J. S. MACLAINE, "Western Atlantic spotted groupers (Teleostei: Serranidae: Epinephelinae): stabilisation of currently used scientific names by neotype designations," *FishTaxa*, vol. 21, pp. 28-59, 2021.
6. A. F. Abdull Razis, M. D. Ibrahim, and S. B. Kntayya, "Health benefits of *Moringa oleifera*," *Asian pacific journal of cancer prevention*, vol. 15, no. 20, pp. 8571-8576, 2014.
7. T. M. Drake *et al.*, "Non-steroidal anti-inflammatory drug use and outcomes of COVID-19 in the ISARIC Clinical Characterisation Protocol UK cohort: a matched, prospective cohort study," *The Lancet Rheumatology*, vol. 3, no. 7, pp. e498-e506, 2021.
8. M. Batlouni, "Nonsteroidal anti-inflammatory drugs: cardiovascular, cerebrovascular and renal effects," *Arquivos brasileiros de cardiologia*, vol. 94, pp. 556-563, 2010.
9. A. Gökçimen, G. Aydin, E. Karaöz, M. A. Malas, and M. Öncü, "Effect of diclofenac sodium administration during pregnancy in the postnatal period," *Fetal diagnosis and therapy*, vol. 16, no. 6, pp.

- 417-422, 2001.
10. M. Vosooghi and M. Amini, "The discovery and development of cyclooxygenase-2 inhibitors as potential anticancer therapies," *Expert opinion on drug discovery*, vol. 9, no. 3, pp. 255-267, 2014.
 11. F. G. Smith, A. W. Wade, M. L. Lewis, and W. Qi, "Cyclooxygenase (COX) inhibitors and the newborn kidney," *Pharmaceuticals*, vol. 5, no. 11, pp. 1160-1176, 2012.
 12. C. J. Patton and S. R. Crouch, "Spectrophotometric and kinetics Investigation of the Berthelot reaction for the determination of Ammonia," *Anal Chem*, vol. 29, pp. 464 -469, 1977.
 13. T. Hirata and S. Narumiya, "Prostanoids as regulators of innate and adaptive immunity," *Advances in immunology*, vol. 116, pp. 143-174, 2012.
 14. C. C. Hernández *et al.*, "Neuroprotective effects of erythropoietin on neurodegenerative and ischemic brain diseases: the role of erythropoietin receptor," *Neural regeneration research*, vol. 12, no. 9, p. 1381, 2017.
 15. P. NANDA and L. TAMANG, "Aborichthys palinensis, a new species of river loach (Cypriniformes: Nemacheilidae) from Arunachal Pradesh, Eastern Himalaya, India," *FishTaxa*, vol. 21, pp. 19-27, 2021.
 16. C. Demarchi, M. d. Souza, L. S. d. Souza, F. L. Galli, and S. M. Pilati, "Lung histopathological changes in Swiss mice exposed to narghile smoke," *Jornal Brasileiro de Patologia e Medicina Laboratorial*, vol. 58, 2022, doi: 10.1900/JBPML.2022.58.444.
 17. J. H. Rojas, M. Paredes, M. Banerjee, O. Akman, and A. Mubayi, "Mathematical Modeling and Dynamics of SARS-CoV-2 in Colombia," *Letters in Biomathematics*, vol. 9, no. 1, pp. 41–56, 2022, doi: 10.30707/LiB9.1.1681913305.229221.
 18. J. D. Bancroft and M. Gamble, *Theory and practice of histological techniques*. Elsevier health sciences, 2008.
 19. A. Romero-Lorca *et al.*, "Artistic swimming in girls: anthropometrics, genotype and athletic performance," *Revista Internacional de Medicina y Ciencias de la Actividad Fisica y el Deporte*, vol. 22, no. 85, p. 199, 2022.
 20. Z. C. Pope, D. J. Barr-Anderson, B. A. Lewis, M. A. Pereira, and Z. Gao, "Use of wearable technology and social media to improve physical activity and dietary behaviors among college students: A 12-week randomized pilot study," *International Journal of Environmental Research and Public Health*, vol. 16, no. 19, p. 3579, 2019.
 21. Z. K. El-Maddawy and I. El-Ashmawy, "Hepato-renal and hematological effects of diclofenac sodium in rats," *Global Journal of Pharmacology*, vol. 7, no. 2, pp. 123-132, 2013.
 22. B. B. Ratliff, W. Abdulmahdi, R. Pawar, and M. S. Wolin, "Oxidant mechanisms in renal injury and disease," *Antioxidants & redox signaling*, vol. 25, no. 3, pp. 119-146, 2016.
 23. R. E. Mostafa, "Potential anti-oxidant and anti-inflammatory effects of losartan against thioacetamide-induced hepatic damage in rats," *Latin Am. J. Pharm*, vol. 37, no. 6, pp. 1089-1096, 2018.
 24. D. A.-H. K. AL-ESSAWI, S. ALJAMALI, and M. JAWD, "The Protective Impact of Vitamin C (Ascorbic acid) against Indomethacin-induced Renal Injury in Embryos and Neonatal (Newborns) Kidneys of White Female Rats During Pregnancy," *International Journal of Pharmaceutical Research (09752366)*, vol. 11, no. 4, 2019.
 25. J. P. I. Lira, J. J. F. Rosa, R. M. Albuquerque, T. A. Pereira, and P. V. T. Vidigal, "Immunohistochemical Evaluation of the Hedgehog Route as a Potential Prognostic Factor in Hepatocellular Carcinoma," *Jornal Brasileiro de Patologia e Medicina Laboratorial*, vol. 58, 2022, doi: 10.1900/JBPML.2022.58.445.
 26. D. A.-H. Kadhim AL–Essawi, A. K. Abed, W. Y. Hashem, A. S. Alhaddad, and Z. M. Mohammad, "Protective Impact of Vitamin C Against Some Fetal and Neonatal Congenital Malformations and Anti Inflammatory Non-Steroidal–Induced Hepatotoxicity of White Rats," *Systematic Reviews in Pharmacy*, vol. 11, no. 11, 2020.
 27. D. Schlondorff, "Renal complications of nonsteroidal anti-inflammatory drugs," *Kidney international*, vol. 44, no. 3, pp. 643-653, 1993.
 28. A. K. Obeid, H. A. A.-A. Alsalam, and R. H. Abdulshahed, "The Role of Moringaoleifera Seed Extract in Amelioration of Kidney Injury Induced by Sodium Nitrite in Male Rats," *Annals of the Romanian Society for Cell Biology*, pp. 2392-2402, 2021.
 29. A. S. Akinrinde, O. Oduwole, F. J. Akinrinmade, and F. B. Bolaji-Alabi, "Nephroprotective effect of methanol extract of Moringa oleifera leaves on acute kidney injury induced by ischemia-reperfusion in rats," *African health sciences*, vol. 20, no. 3, pp. 1382-1396, 2020.
 30. N. C. de Souza Santos *et al.*, "Combinatory activity of linezolid and levofloxacin with antituberculosis drugs in Mycobacterium tuberculosis," *Tuberculosis*, vol. 111, pp. 41-44, 2018.
 31. M. Leyton-Román, C. Córdón, and R. Jiménez-Castuera, "ANALYSIS OF PHYSICAL ACTIVITY AND LIFESTYLES AMONG UNIVERSITY STUDENTS," *REVISTA INTERNACIONAL DE MEDICINA Y CIENCIAS DE LA ACTIVIDAD FISICA Y DEL DEPORTE*, vol. 21, no. 81, pp. 175-195, 2021.
 32. T. Akter, M. Rahman, A. Moni, M. Apu, A. Islam, and A. Fariha, "Prospects for protective potential of Moringa oleifera against kidney diseases. Plants. 2021; 10: 2818," *Plant*, p. 229, 2021.
 33. J. Basivireddy, M. Jacob, A. B. Pulimood, and K. A. Balasubramanian, "Indomethacin-induced renal damage: role of oxygen free radicals," *Biochemical pharmacology*, vol. 67, no. 3, pp. 587-599, 2004.
 34. A.-E. Kadhim and D. Abdel-Hussein, "Effect Study A Nonsteroidal Antiinflammatory Drug (Indomethacin) on Fertility, Some Reproductive Norms and Histological Changes of Fetuses and Newborns of Administered Albino Rats Before Pregnancy," *Systematic Reviews in Pharmacy*, vol. 11, no. 12, 2020.